

Robib and Telemedicine



DANA-FARBER/PARTNERS
CANCERCARE

Affiliated with



HARVARD
MEDICAL SCHOOL

July 2001 Telemedicine Clinic in Robib

Report submitted by David Robertson

On July 12, Sihanouk Hospital Center of Hope nurse Koy Somontha gave the monthly Telemedicine examinations at the Robib Health Clinic. David Robertson transcribed examination data and took digital photos, then transmitted and received replies from Telepartners physicians in Boston and Dr. Jennifer Hines at the Sihanouk Hospital Center of Hope (SHCH) in Phnom Penh. The data was transmitted via the Hironaka School Internet link.

Late on the afternoon of the 12th, nurse Montha decided to transport one patient, Sao Som, to Kampong Thom Provincial Hospital as she was in critical condition and in danger of dying. An e-mail diagnosis arrived a few hours after the nurse, patient, and three family members had departed the village. The e-mail diagnosis agreed with nurse Montha's assessment that this was an emergency case. Because of arriving in Kampong Thom during the evening, after helping the patient get admitted to the hospital, nurse Montha overnighted in Kampong Thom (it's safer not to drive on remote Cambodian roads after dark.) I stayed behind at the village school that evening editing photos and Montha's exam notes, sending e-mail to the hospitals, and organizing several continuing follow up cases (transport, housing, medication, etc.)

Montha was up early, leaving Kampong Thom at 6:00am, and returning to Robib in time for a mid-morning follow up clinic on Friday, July 13th. The follow up consultations were given to the previous day's patients to discuss e-mail advice from the Boston and Phnom Penh doctors. Based on these e-mail recommendations, we offered to transport two patients to Kampong Thom Provincial Hospital that afternoon.

Fortunately, the majority of patients were able to stay home in the village for their follow up care. They needed a medical opinion that we were able to provide via the Internet, and the opinions indicated most of these patients should take medication that we were able to purchase at the village pharmacy. One difficult to fill prescription had to be purchased in Kampong Thom later that afternoon and was sent back to the village via a relative the following morning.

Medication was provided to:

May Telemedicine Patient: **RA VOL**, male, 3 yrs. old
June Telemedicine Patient: **EUNG NGA**, male, 51 yrs. old
June Telemedicine Patient: **SOM TOL**, male, 48 yrs. old
June Telemedicine Patient: **ROS NHEB**, male, 74 yrs. old
June Telemedicine Patient: **SOR SOVANNA**, female, 41 yrs. old
June Telemedicine Patient: **PHIM SICHHIN**, female, 35 yrs. old

Transported and admitted to Kampong Thom Hospital:

July Patient # 7: **TANN KIM NY**, female, 60 years old
July Patient # 9: **PANG PAY**, male, 64 years old
July Patient # 14: **SAO SOM**, female, 45 years old

Transport and sleeping accommodations arranged for outpatient care at Sihanouk Hospital Center of Hope in Phnom Penh:

April patient: PROM CHIM, male, 63 years old (August 10 follow up appointment for abdominal pain at SHCH. Grandfather of Telemedicine patient Phim Sophan.)

February patient: NOUNG KIM CHHANG, male, 48 years old (receives monthly outpatient care and medication for a heart condition, July 18 appointment at SHCH.)

Transport and sleeping accommodations arranged for outpatient care at Kantha Bhopa Children's Hospital and Calmette Hospital in Phnom Penh:

February patient: **PHIM SOPHAN**, male, 14 years old. (Child receives monthly outpatient exams and refill of medication for Tuberculosis at Kantha Bhopa. This child also has a serious heart problem that is monitored monthly with medications refilled at Calmette Hospital in Phnom Penh. He is a candidate for heart surgery at Calmette and may receive an operation in September.)

February patient: **CHHEM LYNA**, female, 1 years old. (Child receives monthly outpatient exams and refill of medication for Tuberculosis at Kantha Bhopa. This child also has a serious heart problem, diagnosed as inoperable, but Calmette Hospital still monitors her monthly and provides refills of heart medication.)

Transport and sleeping accommodations arranged for outpatient care at Kantha Bhopa Children's Hospital in Phnom Penh:

May patient: **CHEA PHEAREAK**, male, 1 year old (Child was diagnosed with a hernia at the May Telemedicine clinic and successfully operated on later that month at Kantha Bhopa. The hospital gave a further diagnosis that this child suffers from TB. The child was advised to return to Kantha Bhopa each month for an outpatient exam and a monthly refill of medication for Tuberculosis. He's taken his TB medication for two months. Usually Kantha Bhopa advises children with TB to take medication daily for eight months.)

Transport and sleeping accommodations arranged for outpatient care at National Pediatric Hospital in Phnom Penh:

June Patient: **SENG SAN**, female, 10 years old (Child was diagnosed with Polyarthritis and was admitted for one month at National Pediatric as a result of the June Telemedicine clinic. For the next year, she's been advised to receive a monthly exam and Penicillin injection given at this government hospital in Phnom Penh. Her next appointment at National Pediatric is August 10.)

Following are the e-mail and photos exchanged between the Telemedicine team in Robib, Telepartners in Boston, and Dr. Jennifer Hines at Sihanouk Hospital Center of Hope in Phnom Penh:

Date: Thu, 12 Jul 2001 02:14:14 -0700 (PDT)

From: David Robertson <davidrobertson1@yahoo.com>

Subject: Robib, Cambodia - Telemedicine Clinic - 12 July - message 1

To: JKVEDAR@PARTNERS.ORG, KKELLEHER@PARTNERS.ORG,

Jennifer Hines <sihosp@bigpond.com.kh>

Cc: dmr@media.mit.edu, bernie@media.mit.edu,

"Hughes, Sherwood" <SHUGHES2@PARTNERS.ORG>, gumley@bigpond.com.kh,

aafc@forum.org.kh

Dear Kathleen/Telepartners & Dr. Jennifer Hines/SHCH:

Hello from Robib, Cambodia. Text and photos attached in the next several messages.

Attached this message:

12 July 2001 Cambodia Telemedicine Clinic - Robib.doc PHIM_Sichhin_1515.jpg

We will hold a follow up clinic at 8:00am on Friday, 13 July (Cambodia time.)

If we could get replies from Boston by the end of your work day on July 12, with the 11 hour time difference, we'll see them in time when I check e-mail at 7:00am on July 13, Cambodia time.

For SHCH, Nurse Montha is hoping to hear from you before 7:00am on Friday morning.

I am only authorized to transport patients to the hospital with advice from Boston and/or Phnom Penh physicians.

Thanks for your help.

Best regards,

David

Telemedicine Clinic in Robib, Cambodia – 12 July 2001

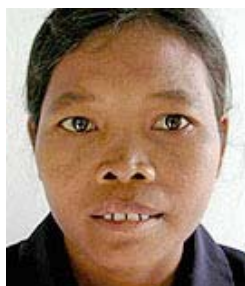Please reply to David Robertson <dmr@media.mit.edu>

We are looking for e-mail advice on the following patients. Any patient records or jpgs not sent is intentional (i.e. non-urgent medical case or unnecessary photos.)

Nurse Montha says the most urgent cases this morning are patient #'s 2, 4, 6.

We will assist transport of patients tomorrow if a physician recommends by e-mail that they be seen at a hospital.

Another e-mail with late morning/afternoon patients will follow later this evening.



Patient #2: PHIM SICHHIN, female, 35 years old

Following data from 14 June clinic in Robib:

PHIM Sichhin, female, 35 years old

Chief complaint: Weakness, palpitations, shortness of breath, sometimes edema all over the body, for the last three years.

BP: 110/60

Pulse: 80

Resp.: 20



Temp. : 36.2

Past history: 10 years ago had malaria but treated well by modern medicine and got resolved.

Lungs: clear both sides

Heart: regular rhythm, positive systolic murmur

Abdomen: soft, flat, not tender

Bowel sound: positive

Skin: warm to touch, no edema, no rash

Urinanalysis: bilirubine +, urobilinogen +

Assessment: Valvular heart disease? Anemia. Chronic Hepatitis.

Recommend: Heart ultrasound, some blood test, chest x-ray, EKG.

June 14/15 replies from Dr. Gumley and Dr. Mudge follow.

From: "Graham Gumley" <ggumley@bigpond.com.kh>

To: "David Robertson" <davidrobertson1@yahoo.com>

Cc: "David Robertson" <dmr@media.mit.edu>

Subject: RE: Resend: Robib, Cambodia - Telemedicine Clinic - 14 June - message 1

Date: Fri, 15 Jun 2001 07:13:01 +0700

Dear David and Montha,

Replies attached -- brief due to time crunch, but practical.

Great work!

Dr. Graham Gumley

SHCH, Phnom Penh

SHCH: Referral to Kampong Thom would be wise to begin these investigations.

(Cardiac surgery will soon be available in Phnom Penh)

From: "Kelleher, Kathleen M., PHS - Telemedicine" <KKELLEHER@PARTNERS.ORG>

To: "David Robertson (E-mail)" <davidrobertson1@yahoo.com>

Subject: FW: Patient #10: PHIM Sichhin

Date: Thu, 14 Jun 2001 15:50:41 -0400

Response from Dr. Gilbert Mudge, BWH Cardiologist

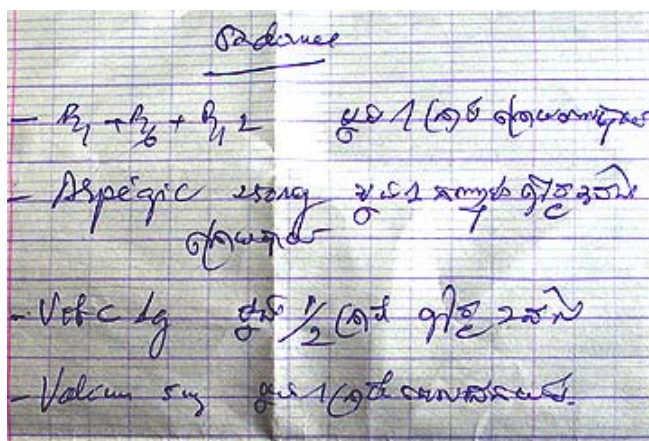
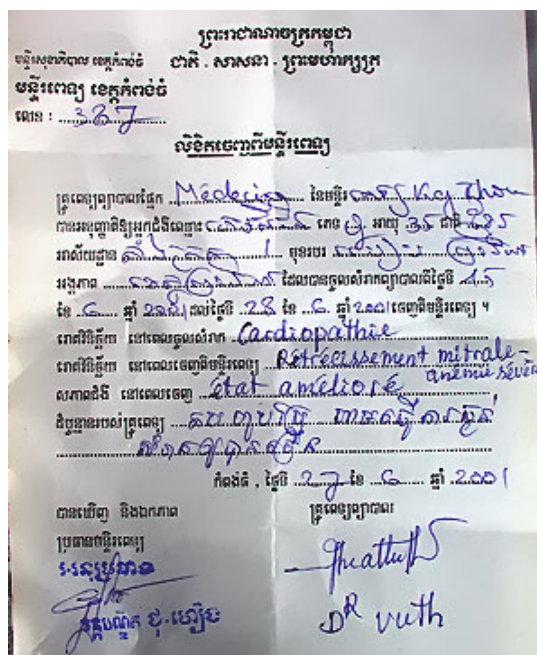
> -----Original Message-----

> From: Mudge, Gilbert Horton, Jr., M.D.

> Sent: Thursday, June 14, 2001 3:33 PM

- > To: Kelleher, Kathleen M., PHS - Telemedicine
- > Subject: RE: Patient #10: PHIM Sichhin
- >
- > With this history and Physical Exam, she certainly needs an echocardiogram
- > plus other W/U as suggested. Based upon her vital signs, physical findings and
- > two photographs, she seems sufficiently stable to fly by helicopter.
- > Unfortunately, I cannot glean much more from the information provided.

Attached are jpgs of medical records from last month's hospitalization at Kampong Thom Regional Hospital:



Following data and photo from 12 July clinic in Robib:

Patient #2: PHIM SICHHIN, female, 35 years old

Chief complaint: Weakness, palpitations, shortness of breath, sometimes edema all over the body, for the last three years.



BP: 100/60
Pulse: 125
Resp.: 24
Temp. : 36.5

Past history: Telemedicine patient last month.

10 years ago had malaria but treated well by modern medicine and got resolved.

Lungs: clear both sides

Heart: regular rhythm, positive systolic murmur

Abdomen: positive splenomegalie, soft

Bowel sound: positive

Skin: pale, warm to touch, no edema, no rash, mild jaundice

Urinanalysis: bilirubine ++, urobilinogen +

Assessment: Valvular heart disease? MR? AS? Anemia.
Chronic Hepatitis.

Recommend: Heart ultrasound, some blood test like CBC, bun. Lyte, creat., chest x-ray, abdominal ultrasound, EKG.

Note: She was a Telemedicine patient last month. Dr. Graham Gumley referred her to Kampong Thom

Hospital. At discharge, she was prescribed ASA, B1, B2, B6, but she is still not better. She still has shortness of breath, weakness, and chest tightness. I would like you to refer her to Sihanouk Hospital Center of Hope. Please let me know clearly. Would like to request an appointment on Tuesday, 17 July, so that the patient could travel and share sleeping accommodations with another poor patient from this village that is being seen at Kantha Bhopa Hospital on 17 July (plus another possible SHCH referral later in this report.)

From: "sihosp" <sihosp@bigpond.com.kh>

To: <dmr@media.mit.edu>

Subject: Telemedicine replies from Jennifer Hines

Date: Thu, 12 Jul 2001 17:51:50 +0700

Hi David and Montha:

The patients below have my reply. Montha, we have to review HPI a little more to get more information from the history.

#2 Phim Sichhin, 35 yr old woman

Based on the medical records that were also sent, this patient has mitral stenosis and severe anemia. The physical findings that you have sent can be due to right sided heart failure, which would explain the periper edema, enlarging abdomen and the absence of crackles in the chest. She was given ASA and vitamin B complex, and we would advise that you add a diuretic (furosemide 20-40mg a day or HCTZ 25-50mg a day) to her regimen and iron/folic acid for the anemia, which we have not yet characterized. The other thought is empiric treatment for parasites that can cause a chronic severe anemia, so we would also recommend Albendazole 400mg Q12 for 3 days.

We do not feel that this woman needs transportation to our hospital.

I hope that this helps. Thanks, Jennifer Hines



Patient #4: Kim Ny, female, 34 years old

Chief complaint: Small mass on anterior neck for one year, chest tightness, sometimes cold extremities.

BP: 100/60

Pulse: 64

Resp.: 20

Temp. : 36.5

Past history: not significant

Lungs: clear both sides

Heart: regular rhythm, no murmur

Abdomen: soft, flat, not tender

Bowel sound: positive

Skin: warm to touch, no rash, no edema, not pale

Neck: mass, size 3 x 3 cm, mobile

Assessment: Simple goiter? Anxiety?

Recommend: Neck ultrasound, blood tests (TSH, T4,) EKG.

On Thu, 12 Jul 2001 17:51:50 +0700, Dr. Jennifer Hines sihosp@bigpond.com.kh wrote:

#4 Kim Ny 34 year old woman

This woman is not very symptomatic for active thyroid disease, although she may have a goiter. I think it is reasonable to get the labwork, but no immediate treatment is necessary.

From: "Kelleher, Kathleen M., PHS - Telemedicine" [<KKELLEHER@PARTNERS.ORG>](mailto:KKELLEHER@PARTNERS.ORG)

To: "David Robertson (E-mail)" [<davidrobertson1@yahoo.com>](mailto:davidrobertson1@yahoo.com)

Cc: "dmr@media.mit.edu" [<dmr@media.mit.edu>](mailto:dmr@media.mit.edu)

Subject: FW: Patient #4: Kim Ny, female, 34 years old

Date: Thu, 12 Jul 2001 20:58:51 -0400

> -----Original Message-----

> From: Daniels, Gilbert H.,M.D.

> Sent: Thursday, July 12, 2001 6:21 PM

> To: Kelleher, Kathleen M., PHS - Telemedicine

> Subject: RE: Patient #4: Kim Ny, female, 34 years old

>

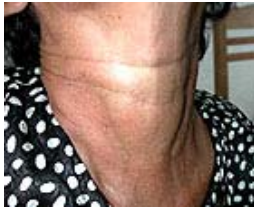> Although most thyroid nodules are benign, we recommend needle aspiration

> biopsy (FNA) of these nodules to be sure that they are not malignant.

> These are done at most medical centers in the US, but I don't know how

- > available the technique would be in Cambodia. Statistically, 96 % will be
- > benign
- > Best
- > Gil Daniels

Following data from 12 July clinic in Robib:



Patient # 6: PHENG Roeung, female, 56 years old

Chief complaint: Shortness of breath, palpitations, dizziness, tremor. Has mass on anterior neck,

size 3 x 3 cm. Sometimes chest tightness during the last four years.



BP: 160/80

Pulse: 140

Resp.: 26

Temp. : 36.5

Past history: not significant.

Lungs: clear both sides

Heart: regular rhythm, no murmur, HR 140

Abdomen: soft, flat, not tender

Bowel sound: positive

Skin: warm to touch, no edema, not pale

Neck: has small mass, size 3 x 3 cm on anterior neck and mobile.

Assessment: Toxic goiter? Mild hypertension.

Recommend: Blood tests (TSH, T4,) Lyte BUN, creatinine, EKG, chest x-ray.

Note: We saw this patient last month, and on advice of Dr. Graham Gumley, referred to Kampong Thom Regional Hospital. The doctor at Kampong Thom gave a diagnosis of hypertension caused by heart disease. They put her on Atenol 50 mg (1/2 tablet per day) and ASA 300 mg (1 per day) and they discharged her from the hospital. But her condition is still not better. Now her shortness of breath and palpitations have increased. So this time, I would like you to give me some advice. My opinion is to refer her to Sihanouk Hospital Center of Hope for evaluation. Would like to request an appointment on Tuesday, 17 July, so that the patient could travel and share sleeping accommodations with another poor patient from this village that is being seen at Kantha Bhopa Hospital on 17 July.

Following background data from 14 June clinic in Robib

PHENG Roeung, female, 56 years old

Chief complaint: Shortness of breath, tingling of limbs, headache, chest tightness and chest pain.

BP: 160/70

Pulse: 160

Resp.: 20

Temp. : 36.5

Past history: One year ago diagnosed with hypertension, BP 185/?.

Lungs: clear both sides
Heart: regular rhythm, no murmur, HR 160 w/ Tachycardia
Abdomen: soft, flat, no pain
Bowel sound: positive
Skin: warm to touch, no rash, no edema
Neck: has small mass, size 2 x 2 cm on anterior neck.

Assessment: Toxic goiter? Mild hypertension.

Recommend: Blood tests (TSH, T4,) EKG, x-ray, iunogram, BUN, creatinine

On Fri, 15 Jun 2001 07:13:01 +0700, "Graham Gumley" ggumley@bigpond.com.kh wrote:

SHCH: Were medications prescribed for the ? Hypertension once diagnoses a year ago? Are they being taken?

The respiratory rate is not high. Ask more about the "shortness of breath". Is it at rest, while lying down, only on exertion or unpredictable?

I see again that we would do well to have a small portable ECG machine to aid in your evaluation.

> From: Kelleher, Kathleen M., PHS - Telemedicine

> Sent: Thursday, July 12, 2001 12:57 PM

> To: David Robertson (E-mail)

> Subject: Patient # 6: PHENG ROEUNG, female, 56 years old

>

> Dear David:

>

> Here is the original response from Dr. Paul Cusick of MGH Internal

> Medicine. It was received by our office on 6/15/01.

>

> *****

> -----Original Message-----

> From: Cusick, Paul S.,M.D.

> Sent: Friday, June 15, 2001 6:48 AM

> To: Kelleher, Kathleen M., PHS - Telemedicine

> Subject:RE: Patient #9, PHENG Roeung

>

> Goiter needs evaluation w/ thyroid function testing and ultrasound/thyroid

> scan . Tachycardia requires EKG and rhythm strip. HTN needs to be treated and

- > controlled. If chest pain is due to Afib, then that would require treatment.
- > However, given age and likely postmenopausal status, ischemic workup needs to
- > be considered. PSC

On Thu, 12 Jul 2001 17:51:50 +0700, Jennifer Hines "sihosp" <sihosp@bigpond.com.kh>

#6 Pheng Roenug 56 yr old woman

Based on the photos and assessment, we feel that this patient may have hyperthyroidism. The patient did not improve on atenolol because this beta blocker will not block the effects of T4 at the periphery. The better drug of choice is propranolol-10mg-20mg BID, to titrate heart rate to 80-90. This patient should have the bloodwork that you have ordered, but we do not think that she needs to be transported to our hospital for additional care because this is our initial treatment plan as we wait for the labs to come back.

On Thu, 12 Jul 2001 06:19:32 -0700 (PDT) David Robertson wrote:

NOTE from David Robertson:

Nurse Montha had to depart the village at 5:30pm tonight with the Social Fund driver, headed for Kampong Thom Hospital. Montha said a 45-year-old female patient named Sao Som was critically ill and might not last the night without hospitalization. Montha advised that three relatives should accompany in case blood is needed. Montha will overnight in Kampong Thom and return to Robib in time for tomorrow morning's follow up clinic. For the rest of the text I send this evening, I will be working from Montha's handwritten notes.



Patient # 7: TANN KIM NY, female, 60 years old

Chief complaint: Stool with blood for five days, epigastric pain for five months.

BP: 140/80

Pulse: 88

Resp.: 20

Temp. : 36.5



Past history: In 1990, also had stool with blood, but was treated with modern medicine. She can't recall name of medication.

Lungs: clear both sides

Heart: regular rhythm, no murmur

Abdomen: soft, flat, not tender, but positive epigastric pain.

Bowel sound: positive

Skin: not pale, warm to touch, no rash, and no edema

Rectal exam: no mass, no pain, but stool with fresh blood. We don't have colo check.

Assessment: GI Bleeding? Dyspepsia?

Recommend: Colo check, some blood tests (CBC, creatine bun lyte,) abdominal ultrasound.

Should we refer her to Kampong Thom Hospital or not?

On Fri, 13 Jul 2001 08:01:28 +0700, Dr. Jennifer Hines sihosp@bigpond.com.kh wrote:

Tann Kim Ny, 60 yr. old woman-

In a woman this age with rectal bleeding, one must always consider a GI malignancy. Doing a coloscopy is really not necessary because frank blood was visualized on examination. Colocheck is used to detect occult blood.

If blood was mixed in with the stool, she may have a bleeding site from either the colon, which is most likely, or a faster bleeding site higher up as in the stomach or small bowel. US-abdomen will not evaluate the bowels very well, so I would suggest that she have a proctoscopic exam or even barium enema, if available and if negative, an upper endoscopy. If the blood is on top of the stool, then she may just have distal rectal bleeding and tumor or hemorrhoids could be the cause. So, if surgical/xray evaluation can be done, I would send to the hospital. Her vital signs appear normal, so transportation should not be a problem. Has she been constipated? Hard stool can aggravate hemorrhoids with much straining and tumor can partially obstruct.



Patient # 8: TANN SOKHA, female, 43 years old

Chief complaint: Epigastric pain, nausea, and sometimes saliva secretion on and off the last seven years.

BP: 100/60

Pulse: 88

Resp.: 20

Temp. : 36.5

Past history: One year ago, she had a gastric ulcer (by fibroscopy) and got better after being treated with modern medicine for one month.

Lungs: clear both sides

Heart: regular rhythm, no murmur

Abdomen: positive epigastric pain, soft, flat

Bowel sound: positive

Skin: warm to touch, no rash, no edema, mild dehydration, and mild pale

Assessment: Malnutrition. Dyspepsia? Parasitosis?

Recommend: Should we treat her in village or refer to Kampong Thom Hospital? If treated in location, please suggest some medication.

On Fri, 13 Jul 2001 08:01:28 +0700, Dr. Jennifer Hines sihosp@bigpond.com.kh wrote:

Tann Sokha, 43 yr. woman

This woman has chronic epigastric pain and dyspepsia is certainly a huge possibility. Many Asians harbor an organism called *Helicobacter pylori* in their stomachs and this bug can cause peptic ulcer disease. I suggest that you can try using a H2 blocker of some type, most are twice a day for six weeks and then reassess, if you have it or send to the hospital for the treatment regimen for *H. pylori* eradication: Bismuth four times a day + doxycycline 100mg or Tetracycline 500mg four times a day + Metronidazole 500mg three times a day with the H2 blocker three times a day all for two weeks. This is an alternative regimen based on what might be available in the area.

On Thu, 12 Jul 2001 19:04:33 -0700 (PDT) David Robertson wrote:

Dear Kathleen/Telepartners & Dr. Jennifer Hines/SHCH:

Thank you for all the quick responses.

Dr. Hines, since we are in the same time zone, this would apply more to you. Nurse Montha is enroute back to Robib now. If we receive any advice on the following, even just quick answers on whether you think transport is necessary today, it will be very useful.

Dr. Hines and Kathy, answers later than this morning will still be followed up on ASAP. I can forward the responses to the teachers at the village school who will pass the advice on to the local health clinic.

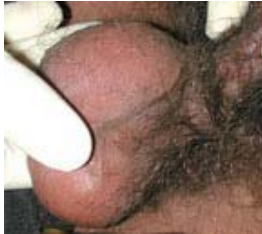Attached this message:

12 July 2001 Cambodia Telemedicine Clinic in Robib - text #3.doc
PANG_PHAY_2029.jpg
PANG_PHAY_2030.jpg

Thanks for your help.

Best regards,

David



Patient # 9: PANG PAY, male, 64 years old

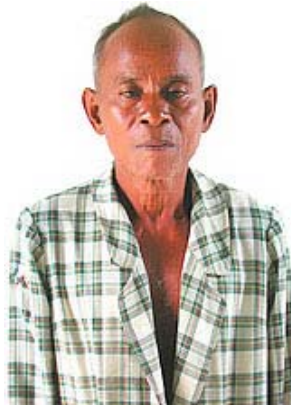Chief complaint: Difficult to pass urine and passing urine with blood. Right scrotum pain and swollen for two days. Coughing up white sputum on and off for three months.

BP: 90/40

Pulse: 100

Resp.: 20

Temp. : 38



Past history: One year ago he had malaria but was treated well by modern medicine. He smokes a lot, five sticks per day for the last five years.

Lungs: Rhonchi on the mild both lobes

Heart: regular rhythm, no murmur

Abdomen: soft, flat, and not tender

Bowel sound: positive

Skin: warm to touch, no rash, no edema, not swollen

Genitals: Right scrotum mild swollen, pain and red. Feels burning.

Urinalysis: Protein: ++, Blood: +

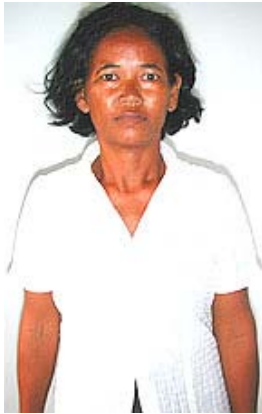Assessment: COPD? UTI? Orchitis? Rule out bladder stone.

Recommend: Abdominal ultrasound, chest x-ray, some blood tests (CBC, creatine, bun lyte,) urine microscopic, sputum for AFB. Should we refer to Kampong Thom Hospital or not?

On Fri, 13 Jul 2001 11:45:51 +0700, Dr. Jennifer Hines sihosp@bigpond.com.kh wrote:

The man, Pang Phay, 64 yr. old. may have an acute infection of the GU tract. The time course is very short. As in the US, this could be due to STD or not. No sexual history was given. The other thing is possible TB, but the timing is not long for this. I would recommend that he be tried on antimicrobial therapy first. One could try ofloxacin or Ciprofloxacin + Doxycycline. His lung complaints could well be due to chronic bronchitis or

just increasing mucus from the smoking. One could get away with the medications above to cover the lung or adding amoxicillin. A rectal exam would be helpful because he may prostatitis and if so, treatment is a lot longer.



Patient # 10: PRING MEY, female, 45 years old

Chief complaint: Mass in the lower abdominal for one month.

BP: 100/60

Pulse: 100

Resp.: 20

Temp. : 36.5

Past history: Not significant.

Lungs: clear both sides

Heart: regular rhythm, no murmur

Abdomen: soft, flat, on the right lower quadrant has a mass, size about 6 x 10 cm and mobile, not painful.

Bowel sound: positive

Skin: not pale, warm to touch, no rash, and no edema

Assessment: Ovarian cyst? Or tumor.

Recommend: Abdominal ultrasound. Should we refer her to Kampong Thom Hospital or not?



On Fri, 13 Jul 2001 11:45:51 +0700, Dr. Jennifer Hines sihosp@bigpond.com.kh wrote:

The last lady, Pring Mey, 45 yr. old woman with a RLQ mass x 1 month would benefit from a pelvic exam. She is asymptomatic or are there obstructive symptoms. What about the last menstrual period? Abd. US is a good test here. I think she is stable enough to reassess and wait to go to the hospital today.

Following patient was transported to Kampong Thom Hospital last night. Do you have any advice for the medical staff at Kampong Thom? We will return to the hospital this afternoon and could pass your suggestions on then. If we receive answers later than late this morning, it is still helpful and we will forward to Kampong Thom Hospital via fax this weekend.



Patient # 14: SAO SOM, female, 45 years old

Chief complaint: Severe abdominal pain for 10 days, shortness of breath for seven days.

BP: 90/40

Pulse: 88

Resp.: 20

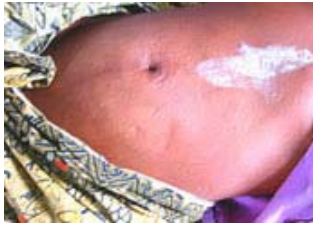Temp. : 36.5

Past history: Unremarkable.

Lungs: crackle on the lower left lung

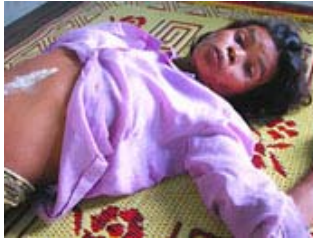Heart: regular rhythm, no murmur

Abdomen: distension, positive pain, hard



Bowel sound: negative
Skin: warm to touch, no rash, mild jaundice, mild pale
Legs: positive pitting edema

Assessment: Peritonitis by appendice perforation? Liver abscess? Septis (bacteria in blood.)



Recommend: Abdominal ultrasound, blood tests, discuss with surgeon. I think we should take her to Kampong Thom Hospital now.

On Fri, 13 Jul 2001 11:45:51 +0700, Dr. Jennifer Hines sihosp@bigpond.com.kh wrote:

I would definitely send the patient, Sao Som, 45 yr.old woman to Kg. Thom Hospital today. She may very well have peritonitis and pneumonia. The other patients could wait.

On Fri, 13 Jul 2001 12:00:37 +0700, Dr. Jennifer Hines sihosp@bigpond.com.kh wrote:

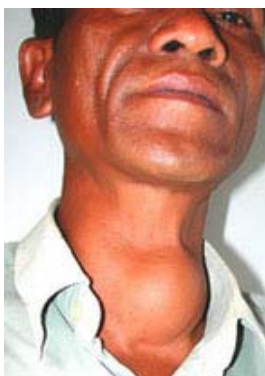Thanks for the update on Sao Som.

On Thu, 12 Jul 2001 21:34:42 -0700 (PDT) David Robertson wrote:

13 July 2001

Nurse Montha is back in the village from Kampong Thom Hospital, conducting the follow up clinic. The patient transported last night, **SAO SOM**, is undergoing surgery this morning for peritonitis. The patient needed a blood transfusion. This patient also has malaria.

Advice that arrives after we depart the village is still welcome. Any necessary transport to the hospital can be arranged during the next few days with the assistance of our schoolteachers at Hironaka School (the village school in Robib that has the Internet link.) I will forward your e-mail to the teachers who will deliver any of your advice to the local health clinic. The patients of the less urgent cases will return to the next Robib Telemedicine Clinic for follow up (dates are August 15 & 16.)



Patient #11: LACH PHAT, male, 52 years old

Chief complaint: Big mass, size 14 x 8 cm, on anterior neck, size increasing day-to-day the last five years. Chest tightness and difficulty swallowing for five months.

BP: 120/80

Pulse: 94

Resp.: 20

Temp. : 36.5

Past history: One year ago he had malaria but was treated well by modern medicine. He smokes a lot, five sticks per day for the last five years.

Past history: Not significant.

Lungs: clear both sides

Heart: regular rhythm, no murmur

Abdomen: soft, flat, not tender or painful.



Bowel sound: positive
Skin: warm to touch, no rash, and no edema
Neck: has a mass, size 14 x 8 cm, on anterior. Mobile but not painful.

Assessment: Simple goiter?

Recommend: Request blood test (TSH, T4.) Neck ultrasound.

Should we refer her to Kampong Thom Hospital or not?

On Fri, 13 Jul 2001 12:00:37 +0700, Dr. Jennifer Hines sihosp@bigpond.com.kh wrote:

Lach Phat, 52 yr old man- Sounds like he has a simple goiter that is now causing compressive symptoms. He needs TSH, Ca+2 and a trip to see the surgeon at Kg. Thom Hospital.



Patient # 12: KONG ROEUT, female, 45 years old

Chief complaint: Cold extremities, poor sleep, weakness, sweating, on and off for the last three years.

BP: 120/80

Pulse: 88

Resp.: 20

Temp. : 36.5

Past history: Not significant.

Lungs: clear both sides

Heart: regular rhythm, no murmur

Abdomen: soft, flat, and not tender.

Bowel sound: positive

Skin: warm to touch, no rash, no edema and not pale

Other systems: normal

Assessment: Anxiety disorder.

Recommend: Encourage her to eat good food like fruit and vegetables and to drink a lot of water.



On Fri, 13 Jul 2001 12:00:37 +0700, Dr. Jennifer Hines sihosp@bigpond.com.kh wrote:

Kong Roeut, 45 yr old woman-- I think this woman may have thyroid disease and so I would recommend TSH, T4. Other things to consider is perimenopause, TB. She can be reassessed in August.

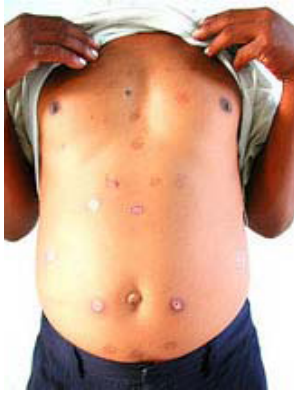Patient # 13: CHEA KIMSOK, male, 40 years old

Chief complaint: Abdominal distension on and off for seven months.

BP: 130/60

Pulse: 84

Resp.: 20



Temp. : 36.5

Past history: Not significant. But he drinks alcohol and smokes too much.

Lungs: clear both sides

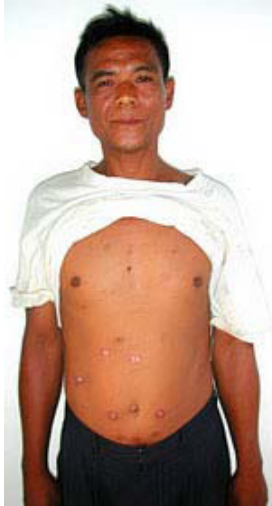Heart: regular rhythm, no murmur

Abdomen: soft, mild tender, negative HSM

Bowel sound: positive

Skin: rash on the face, scars on the abdomen and buttocks (traditional medicine burns.)

Warm to touch, mild jaundice.



Legs: positive pitting edema and numbness on right leg

Urinalysis: Bilirubine ++, Urobilinogen ++, Protein +

Assessment: Hepatitis? Alcohol withdrawal.

Recommend: Blood tests (like lyte, creat., bun., Hep. B or C: transaminase.)

Abdominal ultrasound. Should we refer him to Kampong Thom Hospital for evaluation or not?

On Fri, 13 Jul 2001 12:00:37 +0700, Dr. Jennifer Hines sihosp@bigpond.com.kh wrote:

Chea Kimsok, 40 yr. old man- Would consider alcohol related liver disease and may have cirrhosis, at least in the early stages. I would do what you are recommending in test and just advise the patient to limit fluids, salt, stop all alcohol and eat a well balanced diet daily.
